

A study of inherited short tail and taillessness in Pembroke Welsh corgi

OBJECTIVES: To study whether natural short tail in adult Pembroke Welsh corgi is associated with congenital spinal defects. To report anatomical defects in two newborn tailless puppies from short-tailed parents, and to check whether they were homozygous for the dominant mutation in the T-gene (C295G).

METHODS: The vertebral column of 19 adult dogs with natural short tail, from short-tail×long-tail crossings, was radiographically examined. Two tailless puppies were radiographed and submitted for necropsy. Samples from the puppies, their parents and five siblings were analysed for the mutation of the T-gene.

RESULTS: No congenital spinal defects were diagnosed in any of the short-tailed dogs. The tailless puppies had anorectal atresia, had multiple spinal defects and were homozygous for the mutation in the T-gene.

CLINICAL SIGNIFICANCE: As tail docking is forbidden in many countries, breeding Pembroke Welsh corgis with natural short tail is becoming increasingly common. Previous studies indicated that the mutation in homozygotes is lethal in early fetal life. It is of clinical significance that natural short tail is probably not associated with congenital spinal defects, as is known from studies of other species, and that homozygotes for this mutation with serious anatomical defects may be born.

A. INDREBØ*†, M. LANGE LAND*,
H. M. JUUL‡, H. K. SKOGMO*,
A. H. RENGMARK§ AND F. LINGAAS§

Journal of Small Animal Practice (2008)
49, 220–224
DOI: 10.1111/j.1748-5827.2007.00435.x

*Department of Companion Animal Clinical Science, Norwegian School of Veterinary Science, PO Box 8146 Dep., N-0033 Oslo, Norway

†Norwegian Kennel Club, PO Box 163 Bryn, N-0611 Oslo, Norway

‡Section of Pathology, National Veterinary Institute, PO Box 8156 Dep., N-0033 Oslo, Norway

§Department of Basic Sciences and Aquatic Medicine, Norwegian School of Veterinary Science, PO Box 8146 Dep., N-0033 Oslo, Norway

INTRODUCTION

Inherited short tail has been known in various breeds such as beagle, cocker spaniel and Pembroke Welsh corgi (Pulling 1953, Burns and Frazer 1966, Cattanaach 1996), and is described in the breed standard of other breeds like Brittany spaniel, Bouvier des Flandres, Swedish vallhund and Polish lowland sheepdog (The Kennel Club 1989).

In Corgis, natural short tail has been known for centuries, long before the Pembroke Welsh corgi was first recognised by The Kennel Club (UK) in 1934 (Grey 1939, Hubbard 1951). At this time, the Pembroke was given recognition as a breed separate from his long-tailed cousin, the

Cardigan Welsh corgi. The official breed standard described the tail of the Pembroke as “short, preferable natural” (The Kennel Club 1989). Dogs that were born with long tail, or with a rather long short tail, were docked at an early age. Because of the docking, most breeders did not select for natural short tail in their breeding programmes; therefore, the number of dogs with this characteristic tail declined. After the European Convention for Protection of Pet Animals was concluded in Strasbourg in 1987 and registered by the Secretary-General of the Council of Europe in 1994, tail docking was forbidden by law in an increasing number of countries. Norway was one of the first countries to forbid tail docking (in 1988). As a result, Norwegian Pembroke breeders have been active for a long time in preserving the natural short tail in their breeding stock.

It is known from studies of the Manx cat (Leipold and others 1974) and mice (Herrmann 1991) that specimens with inherited short tail (brachyury) or taillessness (anury) had a higher frequency of spinal defects than their long-tailed relatives. There is no scientifically published study showing whether or not the Pembroke Welsh corgi with inherited short tail is predisposed for spinal defects.

In 2001, Haworth and others reported a mutation in the canine homologue of the T-box transcription factor T, resulting in the failure of the protein to bind to its DNA target which leads to short-tail phenotype in Pembroke Welsh corgi and crossbreed offspring of Pembroke and boxer. The short-tailed dogs were all heterozygous for the mutation in the T factor gene. The offspring of short-tail×short-tail crosses were genotyped without finding any homozygotes. This strongly indicated that the mutation was lethal in homozygotes (Haworth and others 2001). The T-gene is a member of the T-box family of transcription factors consisting of more than 20 genes. The genes play an essential role in controlling many aspects of embryogenesis in a wide variety of species (Showell and others 2004) and can be grouped in at least five subfamilies

of genes (Minguillon and Logan 2003). In mice, mutations in the T-gene are associated with skeletal defects in heterozygotes. Homozygous mutants have severe developmental disorders, and do not survive early pregnancy (Meisler 1997). The human homologue of the mouse T-gene was cloned in 1996 and showed 91 per cent amino acid identity with the murine gene (Edwards and others 1996). Several human developmental disorders have been linked to this group of genes (Packham and Brook 2003). Associations to anorectal atresia have been suspected, but studies in humans lead to the exclusion of the human T-gene as a major candidate gene for sacral agenesis with anorectal atresia (Papapetrou and others 1999).

In 2002, a tailless Pembroke Welsh corgi puppy was brought for examination because of the absence of an anal opening. Both parents had short tail. In 2005 the same combination was repeated, resulting in five puppies. One stillborn had numerous obvious anatomical defects.

The purposes of this study were to investigate whether natural short-tailed dogs, heterozygous for the T-gene mutation, were predisposed to congenital spinal defects, to describe serious anatomical defects in two tailless puppies and to determine whether they were homozygous for the dominant mutation in the T-gene.

MATERIALS AND METHODS

Natural short-tailed dogs

Pedigrees of Pembroke Welsh corgis registered in 1988 to 1997 were obtained from the Norwegian Kennel Club (n=520). The breed club supported information about the natural tail length of the dogs and their parents. Only litters from natural short-tail×long-tail crosses with at least one short-tailed and one long-tailed offspring, living not more than approximately two hours drive from the Norwegian School of Veterinary Science, were included in the study. A total of 29 dogs with natural short tail were invited for examination. Five dogs had moved too far away, three were pregnant at the time of the study and two were dead (seven and nine years old).

The cervical, thoracic, lumbar and sacral vertebral column and the tail of 19 dogs were radiographically examined in 1998 in lateral and ventrodorsal recumbancy with five exposures in each position. If congenital spinal defects were observed in any of these short-tailed dogs, long-tailed littermates would be summoned for examination.

Tailless puppies

Two tailless puppies from the same parents, but from different litters (litter 1 and litter 2), were examined at the Norwegian School of Veterinary Science. The puppies were brought in by the breeder because of obvious anatomical defects. Both parents had natural short tail.

Litter 1 was born in 2002 (five puppies). One puppy (puppy 1) was tailless and had no rectal opening (atresia ani). The puppy, one day old at examination, was euthanased and radiographed in lateral and dorsoventral recumbancy, and submitted for autopsy. Blood (EDTA) was preserved for genetic analysis. The breeder also brought a stillborn long-tailed sibling, which was radiographed next to the tailless puppy, and tissue were preserved for genetic analysis.

Litter 2 was born in 2005 (five puppies). One puppy (puppy 2) was stillborn and had a small body compared with the head, no rectal opening, no tail and a small skinless area in the lumbar region (Fig 1). Radiographic examination was performed, and tissue were preserved for genetic analysis. The puppy was submitted for autopsy, and tissue samples of lung, heart muscle, liver, stomach, kidney and lumbar segments were fixed in 10 per cent neutral-buffered formalin, embedded in paraffin, sectioned at 4 to 6 µm and stained with haematoxylin-eosin. Blood (EDTA) from the parents and the littermates (seven weeks of age) was collected, and the tail length was measured.

DNA purification and mutation analysis

DNA was isolated using Qiagen DNeasy-tissue kit based on the protocol recommendations for purification of DNA. Haworth and others (2001) described a C>G mutation (C295G) in exon 1 of the T-gene associated with the short-tail

phenotype in English and Norwegian Pembrokes. The mutation is located at base pair 189 according to the published GenBank sequence (gi 10636209). Primer sets for PCR and nested primers for sequencing were designed from exon 1 to exon 2.

Primer set 1:

ex1 GAAGAGCCTGCAGTACCGAGT
ex2-326R CACTCTCCGTTACAGT-
ACTTCC

Primer set 2 (nested):

ex1 GAGTGGACCACCTGCTGAG
ex2-272R AAGAACGAGTACATGG-
CGTTG

A standard PCR (primer set 1) was run, and 1 µl of PCR product from primer set 1 was used as a template for the nested PCR. A sequencing reaction was set up using 5 µl purified nested PCR products, and the sequencing reaction was analysed on an ABI PRISM® 3100 Genetic Analyzer (Applied Biosystems).

RESULTS

Short-tailed dogs

No congenital spinal defects were diagnosed in any of the examined short-tailed dogs. Consequently, none of their long-tailed siblings were summoned for examination. The examinations revealed degenerative changes in two dogs. A 10-year-old dog had ventral spondylosis between C2 and C3, with a narrow intervertebral space, and small osteophytes were seen in several places in the lumbar column. Another dog, two years old, had a narrow intervertebral space between C2 and C3 and ventral osteophytes bridging these two vertebrae.

Tailless puppies

Puppy 1 was radiographed next to the stillborn long-tailed sibling with what was interpreted as normal skeletal development (Fig 2). Puppy 1 had air-filled lungs and gas in the intestine and measured 15 cm from skull to caudal thigh. The littermate measured 19 cm.

Puppy 1 had a similar degree of mineralisation of the appendicular skeleton as the littermate. The diaphysis of humerus, radius, ulna, metacarpal bones, P1 and P2

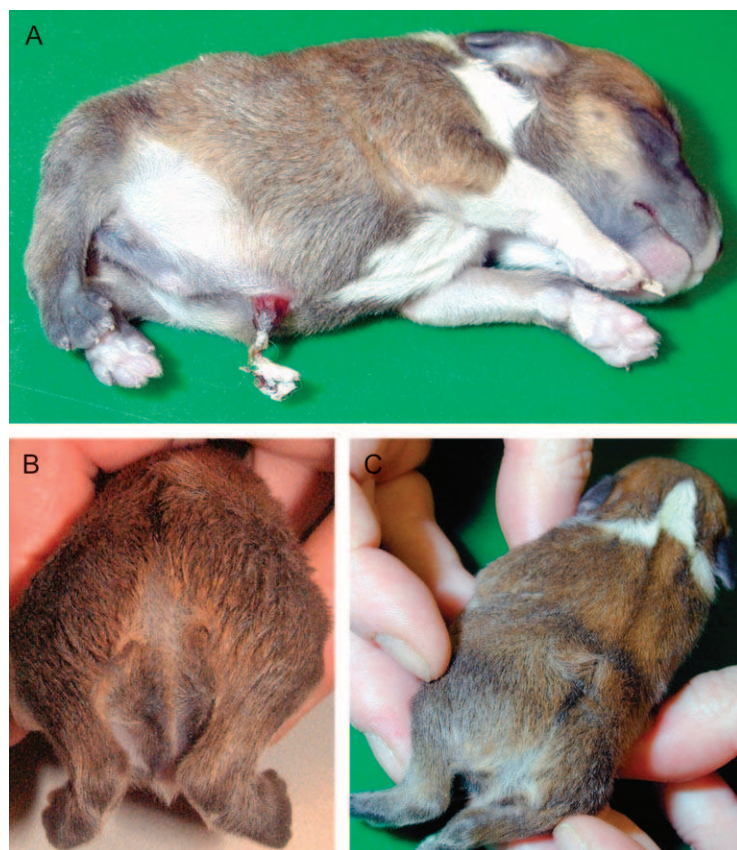


FIG 1. (a) Puppy 2 was 10.5 cm from skull to caudal thigh, had a small body compared with the head and had a compressed ribcage. (b) The tail and the rectal opening were missing. (c) There was an open hernia leading to the spinal canal at the level of the first lumbar vertebra

on the front limbs were mineralised, and in the hind quarter, the femur, tibia, fibula, calcaneus, metatarsal bones and P1, P2 and P3 were mineralised. The miner-

alisation of the skull was similar for the two puppies, apart from the region surrounding the exo-occipital part of the occipital bone, which was united with

the rest of the occipital bone in the normal puppy, although clearly separated in the affected puppy. This puppy had shorter cervical vertebral bodies in the dorsoventral view, particularly C4, and the centrum 2 part of C2 was only faintly mineralised. The differences between the two puppies were more evident in the thoracic spine. Puppy 1 had scoliosis and kyphosis, and only 12 pairs of ribs were visible. The vertebral bodies were moderately shortened in both craniocaudal and dorsoventral views, and spaced more closely than in the normal puppy. The lumbar vertebral bodies of the affected puppy were also shorter in the dorsoventral view, and numbered eight. There was scoliosis of the lumbar vertebral column, and no sacral or caudal vertebrae were seen.

The autopsy showed that the rectum was dilated and filled with meconium and ended approximately 1 cm from the anal area.

Puppy 2 measured 10.5 cm from skull to caudal thigh and weighed 108 g. The littermates had an average birthweight of approximately 400 g according to the breeder.

The puppy was radiographed using computed radiography (Fig 3). This puppy did not have air-filled lungs or intestines. The appendicular skeleton was similarly mineralised as in puppy 1. The axial skeleton also showed similar changes, but the abnormalities were more severe. The cervical vertebral bodies lacked mineralisation of the vertebral body com-

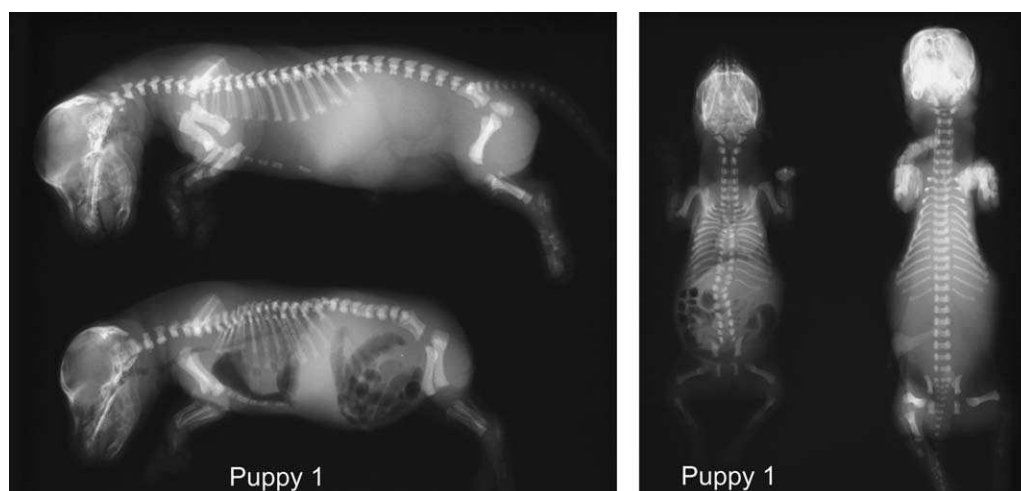


FIG 2. Radiographs of two puppies from litter 1. The tailless puppy (puppy 1) was born alive, the long-tailed sibling was stillborn. Compared with the long-tailed puppy, puppy 1 had shorter cervical, thoracic and lumbar vertebral bodies, and no sacral or caudal vertebrae were seen. The puppy had scoliosis both of the thoracic and lumbar spine, and kyphosis of the thoracic spine. Only 12 pairs of ribs were seen

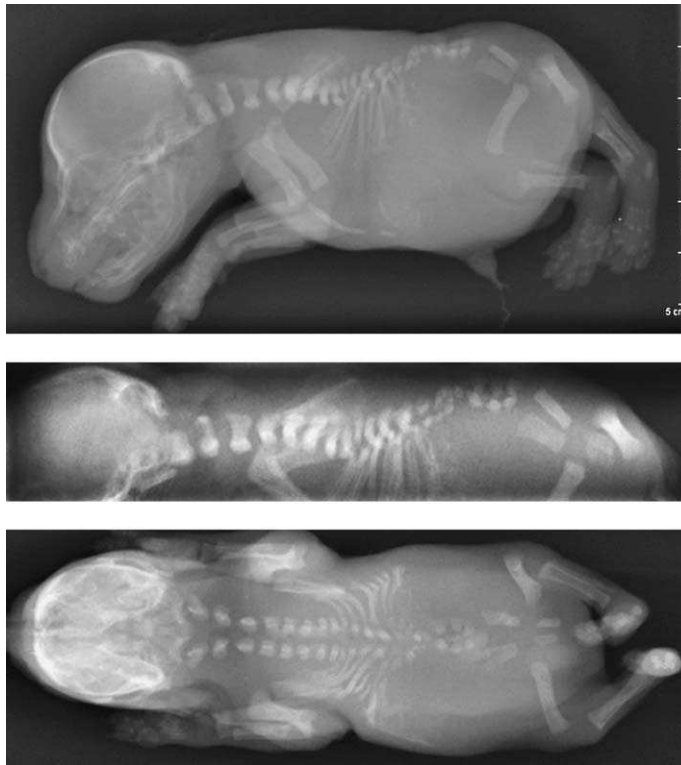

FIG 3. Radiographs of puppy 2 (from litter 2). The lungs were not air-filled, and the defects in the axial skeleton were more severe than those in puppy 1 (Fig 2). The cervical vertebral bodies lacked mineralisation of the vertebral body component. Only the first four pairs of ribs were seen attached to the vertebral body. Three additional mineralised ribs were seen on the left side, four on the right side. The vertebral bodies of the first four thoracic vertebrae lacked mineralisation of the vertebral body segment, but were aligned and in a relatively normal position. The neural arch segments of the remaining thoracic and lumbar vertebrae were small and disorganised and did not include more than eight or nine bodies. The majority of the lumbar vertebral bodies were not seen, nor were the sacral or caudal vertebrae

ponent. In the thoracic spine, only the first four pairs of ribs were seen attached to the vertebral body. In addition, three mineralised ribs were seen on the left side and four on the right side. The vertebral bodies of the first four thoracic vertebrae lacked mineralisation of the vertebral body segment but were aligned and in a relatively normal position. The neural arch segments of the remaining thoracic and lumbar vertebrae were small, disorganised and difficult to count, although these did not likely include more than eight or nine bodies. The majority of the lumbar vertebral bodies were not seen, nor were the sacral or caudal vertebrae. A faintly increased opacity was observed in the region of the cranial abdomen.

At necropsy, the costae of the compressed ribcage were closely set together and partially fused ventrally. There were nine costae on the left side and eight on the right side of the chest. At the level

of the first lumbar vertebra there was an open canal covered with a small crust, leading to the spinal canal. Caudal to this open hernia there were three small, poorly mineralised vertebrae partially fused together laterally and without closure dorsally. Further caudal vertebrae and os

sacrum were absent. In the umbilical cord area, there was a small hernia with parts of jejunum included, but with passage for intestinal contents. The lungs were small and the cranial lobes were fused together ventrally. The stomach was partially dislocated craniodorsally to the liver. The rectum was atretic and ended at the entrance to the pelvic cavity, and the anus was atretic.

Microscopic examination revealed atelectatic lungs and focal subcapsular necrosis without inflammatory cells in the liver. In the lumbar vertebra segments, there were areas of cartilage and bone tissue ventrally. The central spinal cord was absent and nerve tissue and muscle tissue were present in the periphery of the vertebral segment.

DNA analyses

DNA was sequenced for mutation analysis of the T-gene. Both parents and the short-tailed puppies were heterozygous for the dominant mutation in the T-gene (C295G). The two tailless puppies were homozygous for the mutation (GG). The two long-tailed puppies had genotype CC.

Figure 4 shows the pedigree of the two litters.

DISCUSSION

Although the 19 adult short-tailed dogs were not genotyped, they are assumed to be heterozygote for the dominant mutation in the T-gene, as they were all from short-tail×long-tail crosses. The study showed a major variation in the phenotypic expression of the mutation in the T-gene, depending on whether the dog

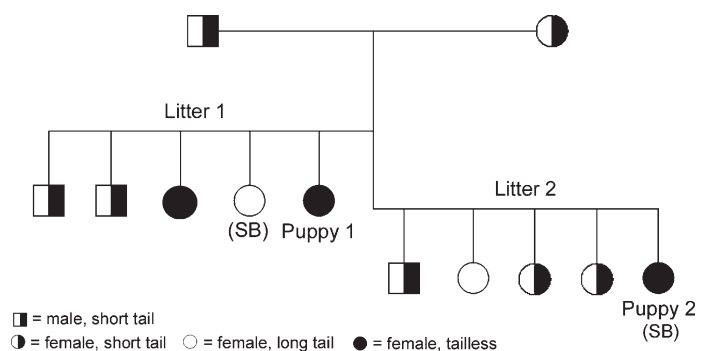


FIG 4. Pedigree of two litters from identical crossings of two short-tailed (heterozygous) dogs. One long-tailed female in litter 1 and the tailless female in litter 2 (puppy 2) were stillborn (SB). The tail of the parents measured 3 and 5 cm. The tail lengths of the puppies of litter 2, at seven weeks of age, were from 4 to 7 cm for the short-tailed puppies, and 15 cm for the long-tailed puppy

was heterozygous (CG) or homozygous (GG) for the mutation. The only effect of the gene in heterozygotes revealed in this study was a distinct shortening of the tail. This is different from the mouse, but in accordance with zebrafish heterozygous for the mutation in the T-orthologue "no tail," that does not exhibit any obvious phenotypic defects (Schulte-Merker and others 1994).

Haworth and others (2001) genotyped all puppies from four independent Pembroke Welsh corgi short-tail \times short-tail crosses. All the 13 short-tailed puppies in these litters were heterozygous for the dominant mutation in the T-gene, and the long-tailed puppies did not carry this mutation. No homozygotes were found in their study. They concluded that this strongly indicates that this mutation in the T-gene is lethal in homozygotes ($P=0.0045$), as might be predicted from the studies of the T-box genes in mice (Herrmann 1991, Chapman and others 1996, Showell and others 2004).

Our study is the first to report dogs that are homozygous for this mutation. The puppies were from two litters, with a total of 10 puppies, from the same short-tail \times short-tail crossing. Two of the puppies had long tail, six had short tail (heterozygous) and two had no tail at all and were homozygous for the mutation. Our study of the two tailless puppies shows that there is a considerable variation in the extent of defects caused by the mutation in the T-gene in homozygotes. The fact that there are no other reports of homozygote puppies or dead fetuses delivered at the time of birth suggests that in the majority of cases the homozygote GG combination is lethal in early fetal life. This is in accordance with the mouse brachyury gene where the homozygous mutants die around day 10 of pregnancy (Showell and others 2004).

Both the homozygous puppies described in this article had serious defects not consistent with life, although the defects were far more excessive in puppy 2. They both had anorectal atresia and major spinal defects. Puppy 2 was described as stillborn as both the radiographs and the necropsy showed that the lungs had not expanded. The breeder had observed that the puppy seemed to

gasp for air when it was born but died after only a few seconds. This could suggest that the puppy was momentarily alive after birth. The puppy had a more or less normal-sized head but a very short and compressed body, and it was obvious to the breeder that this puppy had extensive anatomical defects. Puppy 1, on the other hand, was born alive and had no obvious breathing problems when it was brought to the clinic. It was only slightly smaller than the littermates; the difference in size was not more pronounced than that observed in normal litters. These two puppies show that homozygotes for the T-gene are seldom able to stay alive until the time of birth and even survive for a short time. The molecular reason for this variation is not obvious. The natural variation in tail length in the short-tailed Pembroke Welsh corgi indicates that there is variation in other genes directly interacting with the T-gene. It has been shown that there may be complicated interactions between the different genes in the T-box family and their cofactors (Packham and Brooks 2003). Dixon and Dixon (2004) showed that the genetic background has a major effect on the penetrance and severity of a gene (TCOF1) involved in skeletal development. A unique combination of alleles of genes interacting with the T-gene in the two parents of the two litters could explain the phenotype of these two unique puppies.

The fact that this study revealed no spinal defects in any of the presumed heterozygous short-tailed adults is highly suggestive that the only effect of the T-gene in heterozygotes is a short tail. A short-tail \times long-tail crossing will give about 50 per cent short-tailed offspring. Based on the presented data, we can see no ethical problems in such mating. Short-tail \times short-tail crosses have been performed repeatedly both in Norway and in other countries in the past years, but no puppies with any defects have been reported elsewhere. Because this study is the only report of excessive defects in homozygotes and there are no other reports of homozygotes being born, the probability of obtaining puppies with defect from short-tail \times short-tail crossings should be considered to be low. Breeding

of dogs with genotypes that can give rise to defects should, however, not be performed. If future data indicate that homozygous puppies with defects are born, and that the two described cases are not rare exceptions, crossing of two heterozygotes for the T-mutant should not be recommended.

References

- BURNS, M. & FRAZER, M. N. (1966) *The Genetics of the Dog*. 2nd edn. Edinburgh, UK: Oliver and Boyd LDT, p 34-35
- CATTANACH, B. (1996) Genetics can be fun. *Dog World Magazine* (UK), August to September Issues. <http://www.steynmere.com/GENETICS.html#articles>. Accessed January 24, 2007
- CHAPMAN, D. L., AGULNIK, I., HANCOCK, S., SILVER, L. M. & PAPAIOANNOU, V. E. (1996) Tbx6, a mouse T-box gene implicated in paraxial mesoderm formation at gastrulation. *Developmental Biology* **180**, 534-542
- DIXON, J. & DIXON, M. J. (2004) Genetic background has a major effect on the penetrance and severity of craniofacial defects in mice heterozygous for the gene encoding the nucleolar protein Treacle. *Developmental Dynamics* **229**, 907-914
- EDWARDS, Y. H., PUTT, W., LEKOAPE, K. M., STOTT, D., FOX, M., HOPKINSON, D. A. & SOWDEN, J. (1996) The human homolog T of the mouse T (Brachyury) gene; gene structure, cDNA sequence, and assignment to chromosome 6q27. *Genome Research* **6**, 226-233
- GREY, T. (1939) *The Welsh Corgi. Pembrokeshire and Cardiganshire Types*. London, UK: Watmoughs Limited
- HAWORTH, K., PUTT, W., CATTANACH, B., BREEN, M., BINNS, M., LINGAAS, F. & EDWARDS, Y. H. (2001) Canine homolog of the T-box transcription factor T; failure of the protein to bind to its DNA target leads to a short-tail phenotype. *Mammalian Genome* **12**, 212-218
- HERRMANN, B. G. (1991) Expression pattern of the Brachyury gene in whole-mount TWis/TWis mutant embryos. *Development* **113**, 913-917
- HUBBARD, C. L. B. (1951) *The Pembrokeshire Corgi Handbook*. London, UK: Nicholson & Watson
- LEIPOLD, H. W., HUSTON, K., BLAUCH, B. & GUFFY, M. M. (1974) Congenital defects of the caudal vertebral column and spinal cord in Manx cats. *Journal of the American Veterinary Medical Association* **164**, 520-523
- MEISLER, M. H. (1997) Mutation watch: mouse Brachyury (T), the T-box gene family, and human disease. *Mammalian Genome* **8**, 799-800
- MINGUILLON, C. & LOGAN, M. (2003) The comparative genomics of T-box genes. *Briefings in Functional Genomics and Proteomics* **2**, 224-233
- PACKHAM, E. A. & BROOK, J. D. (2003) T-box genes in human disorders. *Human Molecular Genetics* **12**, Spec No 1, R37-R44
- PAPAPETROU, C., DRUMMOND, F., REARDON, W., WINTER, R., SPITZ, L. & EDWARDS, Y. H. (1999) A genetic study of the human T gene and its exclusion as a major candidate gene for sacral agenesis with anorectal atresia. *Journal of Medical Genetics* **36**, 208-213
- PULLING, T. (1953) Anury in cocker spaniels. *Journal of Heredity* **55**, 105-107
- SCHULTE-MERKER, S., VAN EEDEN, F. J., HALPERN, M. E., KIMMEL, C. B. & NUSSLEIN-VOLHARD, C. (1994) No tail (ntl) is the zebrafish homologue of the mouse T (Brachyury) gene. *Development* **120**, 1009-1015
- SHOWELL, C., BINDER, O. & CONLON, F. I. (2004) T-box genes in early embryogenesis. *Developmental Dynamics* **229**, 201-218
- The Kennel Club (1989) *The Kennel Club's Illustrated Breed Standards*. London, UK: The Bodley Head